



ACADEMIC  
PRESS

Available online at [www.sciencedirect.com](http://www.sciencedirect.com)

SCIENCE @ DIRECT®

NeuroImage 20 (2003) S132–S138

NeuroImage

[www.elsevier.com/locate/ynimg](http://www.elsevier.com/locate/ynimg)

## Psychogenic amnesia

Hans J. Markowitsch\*

*Physiological Psychology, University of Bielefeld, D-33501 Bielefeld, Germany*

### Abstract

Time- and content-based memory systems are briefly described so that their importance for a refined analysis of memory disturbances becomes evident. These memory systems are then related to their brain instantiation, emphasizing that there are limbic circuits for encoding different forms of memories, largely cortical networks for memory storage, and a combined temporofrontal network acting to trigger information retrieval. The terms functional amnesias and psychogenic amnesias are discussed and their symptomatology is compared to that of organic amnesias. The term “mnestic block syndrome” is introduced and defined as a syndrome of its own. Experimental data, obtained especially with functional imaging methods, are presented to elucidate changes in neural activation during functional amnesic states. It is concluded that functional amnesic states, confined to a patient’s biography, can be triggered by environmentally induced stress and trauma, leading to lasting inability to retrieve autobiographical events. Such an impairment may be identified at the brain level using functional imaging techniques.

© 2003 Elsevier Inc. All rights reserved.

### Introduction

Commonly, memory disturbances are related to organic brain damage. Nevertheless, especially the old psychiatric literature provides numerous examples of patients with selective amnesia due to what at that time was preferentially named hysteria (Markowitsch, 1992) and which implied that both environmental circumstances and personality traits influence bodily and brain states to a considerable degree. Awareness of the existence of relations between cognition, soma, and psyche has increased especially in recent times and has created the research branch named cognitive neuropsychiatry. Within this branch, psychopathologic processes, deviating from normal information processing, are studied with a combination of methods derived from neurology, psychiatry, psychology, neurobiology, and neuroinformatics in order to provide a deeper understanding of psychic disease processes (Halligan and David, 2001).

I will discuss psychologically based memory disorders by first providing an introduction into memory systems and corresponding brain networks and thereafter by introducing

forms of “nonorganically” caused memory disturbances and their possible functional brain correlates.

### Multiple memory systems

Memory can be described with respect to time and contents, with the time-based division usually referring to ultra-short-term, short-term, and long-term memory. Ultra-short-term memory is usually split into iconic and echoic memory for the visual and auditory modality, respectively. Its duration amounts to up to hundreds of milliseconds (Cowan, 1984). Short-term memory lasts from seconds to minutes or includes 4 to less than 10 bits (Miller, 1956; Yoshino, 1993; Cowan, 2000). Working memory is a special form of short-term memory and includes beyond the encoding the active holding and manipulating of information over a limited time duration (“online processing”; Baddeley, 2000). All beyond the capacity of short-term memory is assigned to the long-term memory store. Especially in patients with memory disturbances the distinction between old and new memory is of importance or, with respect to the pathological condition, that between retrograde amnesia (inability to retrieve previously stored memories) and anterograde amnesia (inability to form new memories long term).

In addition to the traditional time-based division of mem-

\* Fax: +495211066049.

E-mail address: [hjmarkowitsch@uni-bielefeld.de](mailto:hjmarkowitsch@uni-bielefeld.de)

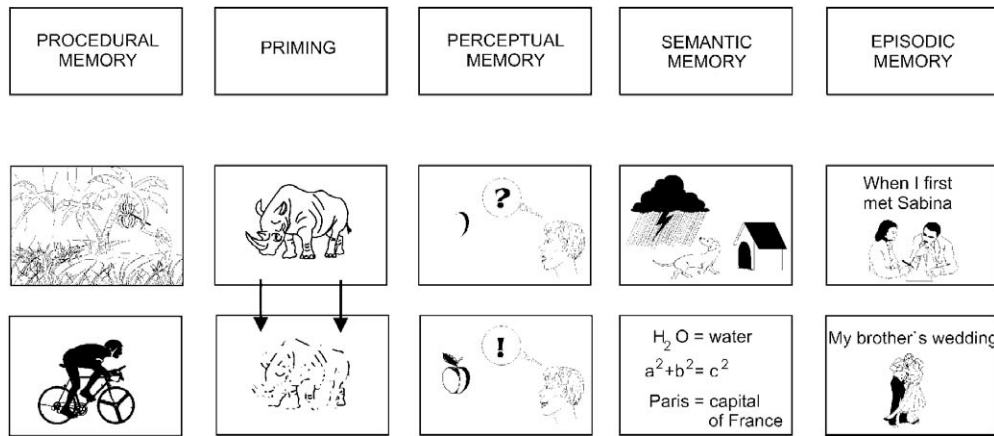


Fig. 1. Five divisions of long-term memory.

ory there is a contents-based one which includes—hierarchically arranged from the complex to the simple—the following systems: the episodic form of memory as a past-oriented memory system which requires conscious reflection and allows mental time traveling (autobiographical events are included in this system); the semantic memory system, a present-oriented fact system; perceptual memory as a system related to familiarity judgments: the priming system which facilitates the nonconscious processing of previous perceptions; and procedural memory, related to sensorimotor skills (Fig. 1).

### Memory and brain

Information processing can be divided into the stages of encoding, consolidating, storage, and retrieval. For encoding, especially structures of the limbic system constitute so-called bottlenecks through which information has to pass (at least episodic and semantic information) (Brand and Markowitsch, 2003). Time duration of the process of consolidation varies considerably (McGaugh, 2000; Piefke et al., 2003). The majority of information is stored within cerebral cortical networks whereby so-called limbic structures participate especially for episodic-autobiographical events (Markowitsch, 2003). For the retrieval of episodic and semantic memories, especially regions of the temporo-frontal junction area, interconnected via the uncinate fascicle, are engaged as trigger structures, activating the cortical networks (Fink et al., 1996; Markowitsch, 2003).

Of special importance is the role of emotions for memory processing. Here structures such as the amygdala, the septal nuclei, and portions of the cingulate gyrus are centrally engaged. In a functional imaging study on healthy subjects, these showed right-hemispheric amygdala and ventral prefrontal activations when retrieving autobiographical episodes, but not when retrieving fictitious episodes (Markowitsch et al., 2000b).

### Dissociative disturbances

There exist numerous case reports, already from the late 19th and early 20th centuries, describing patients with massive memory disturbances due to psychic alterations (Markowitsch, 1992). Among them were patients with hysterical or dissociative states, such as the Ganser syndrome, a state of multiple personality or “Wanderlust” (Markowitsch, 1992). Such patients are characterized by an inability to remember their personal past, sometimes (in the psychogenic fugue condition) combined with a sudden leaving of the home and apparently aimless traveling to a distant locus. This is accompanied by a loss of one’s own identity and the acceptance of a new one. Such dissociative conditions are usually provoked by single or repeated stress and trauma events. Dissociations function to fragmentize, derealize, and depersonalize traumatic experiences. Due to these functions they may manifest themselves in daily life and remain active for prolonged periods of time. Acute dissociative reactions toward a trauma appear to be an indicator for the later development of a posttraumatic stress disorder.

At present a number of patients with psychogenic or functional amnesias have been described who show distinct memory disorders in the autobiographic domain and in part also demonstrate alterations in their brain metabolism, compared to nonamnestic subjects (Markowitsch, 1999). One account of functional amnesia is that it is caused by an altered release of or an imbalance in stress hormones (glucocorticoids, mineralocorticoids) at the brain level (de Kloet et al., 1999), blocking normal autobiographical memory processing (Markowitsch, 2000a,b, 2002a,b). These changes are followed by a more general imbalance of neurotransmitters and hormones altogether (McEwen, 1999, 2000).

Exposure to stress and trauma situations in early childhood seems to facilitate the outbreak of a posttraumatic amnesia symptomatology in later life (Markowitsch, 2000a,b) and seems to damage the brain’s neuropil and

possibly even neurons in toto (Bremner, 2001; Kim and Yoon, 1998; McEwen, 1999, 2000; O'Brien, 1997; Schore, 2002). For example, it was found that individuals who had been repeatedly sexually abused as children manifest changes in the brain's morphology and show deviances in behavior (Anderson et al., 2002). The recent book by Bremner (2002) summarizes many results. Especially regions of the expanded limbic system of the right hemisphere seem to be vulnerable to stress and trauma experiences; similarly, body opioids and other hormones and neurotransmitters (e.g., noradrenalin, serotonin, neuropeptide Y) are affected. Chronically heightened levels of corticosteroids may lead to accelerated aging processes (Porter and Landfield, 1998). Changes in receptor density of glucocorticoids and mineralocorticoids may affect anterior temporal lobe, orbitofrontal, hippocampal, and amygdalar regions in particular. Possibly a dysregulation in the gene expression of corticosteroid receptors, combined with an inhibition of neurotrophic factors during chronic stress conditions, is causal for the morphological changes found (Meyer et al., 2001; Nam et al., 2000).

The interaction between emotional processing and cognitive memorizing is, for patients with posttraumatic stress disorder, of special interest, as such patients experience intensive flashbacks or intrusions, but are frequently unable to verbalize them as they exist frequently in a disorganized form. Brewin (2001) assumes that highly emotional information, as exists for instance during dreams, provokes massive and basal conditioned reactions and—at the same time—hampers the formation of conscious memory processes (see, e.g., the patient described in Markowitsch et al., 1997b). Also with respect to early childhood traumata, a dissociation seems frequently to exist between explicit remembrances and traumatic, usually more picturesque and difficult to verbalize, experiences. LeDoux (2000) assumes that ontogenetically early occurring emotional experiences (such as traumata) are encoded and stored via limbic regions, in particular the amygdala; as verbalizing is not possible at this stage, a verbal script is missing for recall in later life.

### **Functional amnesias: comparison with organic amnesias**

Organic retrograde amnesias most frequently occur after bilateral damage of medial or anterior temporal and/or prefrontal regions of traumatic origin. More rarely, medial diencephalic lesions and etiologies such as hypoxias, encephalitis, or vascular pathology are related to retrograde amnesias. Examples are the patients described by Markowitsch et al. (1993) and Kroll et al. (1997) with mainly right-hemispheric trauma-caused temporofrontal damage and a severe and lasting amnesic condition which was largely restricted to the retrograde autobiographical memory domain. An early functional imaging study confirmed these

and neighboring limbic regions of the right hemisphere as centrally engaged in the retrieval of old autobiographical events (Fink et al., 1996).

Patients with retrograde autobiographical amnesia without brain damage (or with concussions only) usually manifest psychic or psychiatric problems; sometimes, the reverse symptom picture with anterograde instead of retrograde autobiographical amnesia occurs (Markowitsch et al., 1999b). A direct and universal connection between a psychic background of such amnesias could not always be established (Lucchelli and Spinnler, 2002); therefore, some authors prefer to use the expression “functional amnesia” (De Renzi et al., 1997). It is, however, possible to see—at least in a few patients—metabolic brain changes in the memory processing regions of these patients' brains (Markowitsch et al., 1997a, 1997b, 1998, 2000a).

In comparison to patients with direct organic brain damage, patients with functional amnesia frequently manifest additional “somatizations” such as leg weaknesses, anomia, and palsies (Kritchevsky et al., 1997) and show a history of psychiatric illnesses. On the other hand, patients with organic and functional amnesias have in common that they frequently show an emotional flattening and insufficient insight into their disease condition (Markowitsch, 1999). In a single case of a patient with dissociative amnesia, Yasuno et al. (2000) showed a largely right-hemispheric activation during the retrieval of semantic facts during the acute and a change to the left hemisphere after recovery. It was assumed that this deviance in the activation pattern (compared to normals) was due to an increased binding to anxiousness and other negative emotions during the acute stage. A related finding had been reported earlier in the case report of Markowitsch et al. (1997a), who had found that a patient with a psychogenic fugue condition activated largely left-hemispheric frontotemporal regions when being confronted with his own life episodes, while normal subjects activated a very similar network in their right hemisphere (Fink et al., 1996). Another patient likewise manifested a massively reduced perfusion in his right frontotemporal hemisphere as measured with single photon emission computed tomography (Markowitsch, 1999) (Fig. 2). It can therefore be assumed that patients with functional amnesias demonstrate an imbalance in their brain activity so that the retrieval of autobiographical events becomes blocked. In this respect the report by Costello et al. (1998) is of particular relevance. The patient in his 40s had a left superior dorsomedial prefrontal hemorrhage (of about 2 cm in diameter) and dense retrograde amnesia for his past 19 years. Costello et al. did a PET study on him in which he attempted to recall events using family snapshots as stimuli. They found that for the amnesic period he showed greater activation in the precuneus and less activity in the right ventrolateral prefrontal cortex (and in his damaged area). They argued that portions of the right temporofrontal region, proposed by Fink et al. (1996) to be engaged in the retrieval of emotional events of the personal past, did not properly trigger the

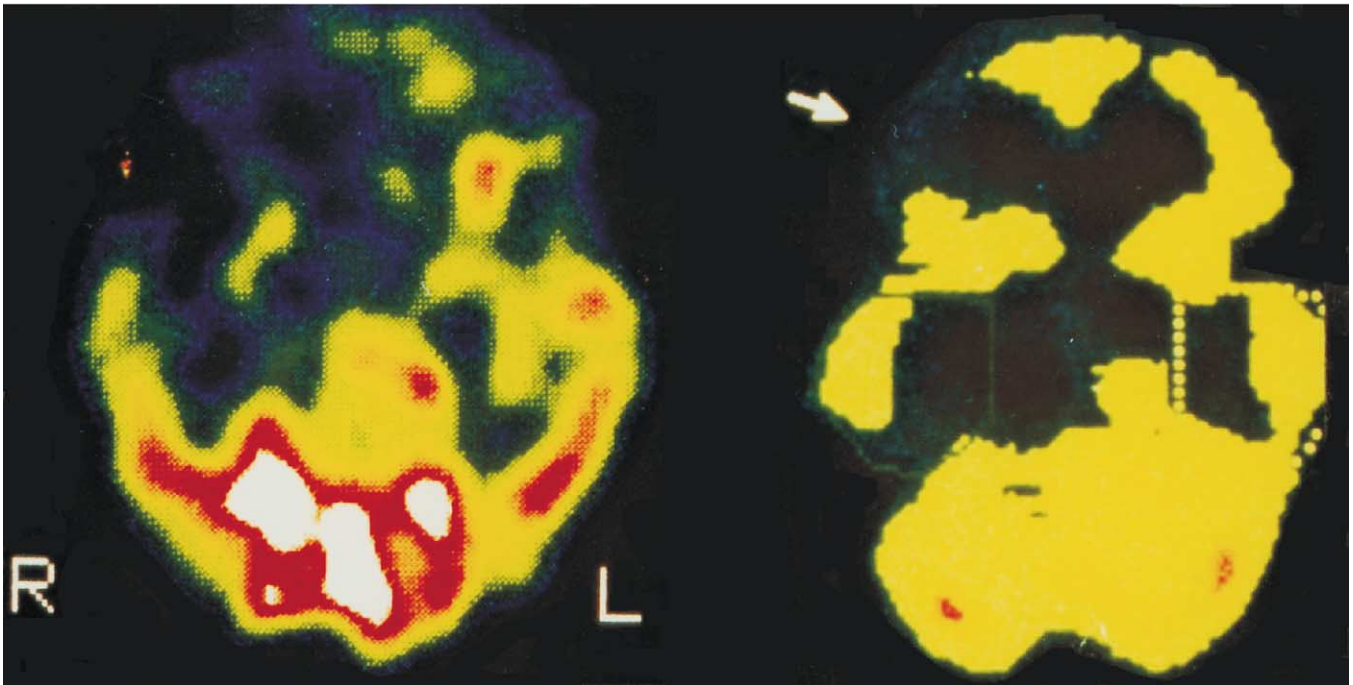


Fig. 2. Horizontal SPECT images through the brains of two patients with selective retrograde amnesia for autobiographical information. The section on the left is from a patient with a probable organically based amnesia (herpes simplex encephalitis). It was done 3 years postinfection and demonstrates the area of hypoperfusion in the right temporofrontal region. The section on the right shows the brain of a patient with probable psychogenic amnesia. Again, a significant metabolic reduction is visible in the right temporofrontal junction zone. L, left; R, right (from Plate 2 of Markowitsch, H.J., 1999, *Functional neuroimaging correlates of functional amnesia. Memory* 7, 561–583. Reprinted by permission of Psychology Press Ltd., Hove).

recursive self-cueing of memory traces. In their eyes both the effects of the brain damage and the predisposing psychological factors interacted causally in leading to the retrograde episodic amnesia.

Fig. 3 provides a schematic of the underlying neural network which is assumed to be engaged in retrieving personal events. Interestingly, a recent study found for normal subjects that the uncinate fascicle—connecting the relevant frontotemporal regions engaged in triggering the retrieval of episodic (right hemisphere) and semantic memories (left hemisphere)—is 27% larger and contains 33% more fibers in the right, compared to the left, hemisphere (Highley et al., 2002).

### Mnemonic block syndrome

A few years ago, we proposed a syndrome, which we named “mnestic block syndrome” (Markowitsch, 1998, 2000b, 2002b; Markowitsch et al., 1999a, 2000a) and considered to be related to an altered brain metabolism which may include changes in various transmitter and hormonal systems (GABA-agonists, glucocorticoids, acetylcholine) and leads to a block in memory performance, usually on the retrograde autobiographical, but sometimes on the anterograde amnesic site; the syndrome may be accompanied by

further impairments in cognitive functions. The syndrome develops on the basis of single or multiple stress and trauma conditions and may have a background of related stress or trauma conditions in early childhood. It can be interpreted as a disconnection syndrome, as the connection between the trigger structures for retrieval and the storage sites is blocked (or—for the anterograde block—the connection between the encoding and the storage sites) (cf. the cases of Costello et al., 1998; Kroll et al., 1997; Markowitsch et al., 1997a, 1997b). The mnestic block syndrome is that part of the dissociative disturbances whose acute cause can be traced back to somatic illnesses and whose cognitive deteriorations go beyond the amnesia for single events (as, e.g., in posttraumatic stress disorder), but where, on the other hand, self-identity may be preserved. Social, occupational, and other important fields of life are usually impaired. The syndrome is not explainable by willed simulation. Willed simulation would be detectable with various tests on faking such as the TOMM test (Tombaugh, 1996) and other memory tests (Iverson and Franzen, 1996; Leng and Parkin, 1995) and would most likely be visible with functional imaging methods, as is suggested by the outcome of the studies of Markowitsch et al. (1997a, 2000b). The mnestic block syndrome most likely manifests itself in a way analogous to the mechanisms of endogenous pain inhibition, appearing under extreme stress, and can be seen as a com-

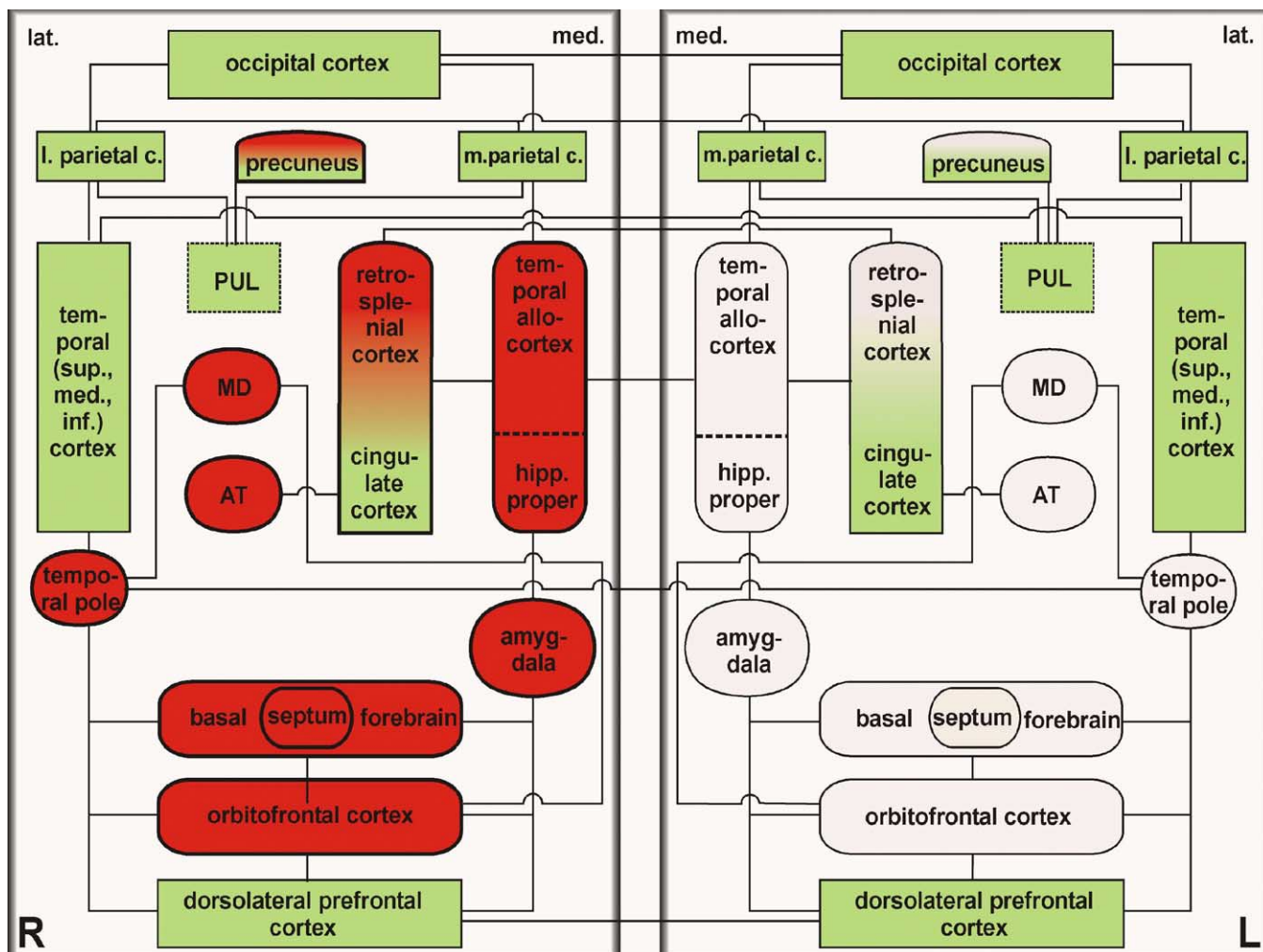


Fig. 3. Schematic of the two cerebral hemispheres with some of the structures related to memory processing, in particular to the retrieval of stored information. It is assumed that limbic structures of the right hemisphere are much more strongly engaged in retrieving autobiographical information than those of the left hemisphere and that in principal the right hemisphere is heavily involved in retrieving episodic-autobiographical information while the left one mainly retrieves semantic material.

bined consequence of environmental influences and intrapsychic processes (Thomas-Antérion and Truche, 1998).

## Conclusions

Modern imaging methods have helped to establish similarities between different forms of amnesias with respect to their brain correlates. It was found that also environmental-related amnesias—caused by stress and trauma situations with which individuals cannot cope appropriately—may alter the brain's metabolism in a predictable way and that even therapy-induced reestablishments of memory may be related to gains in brain metabolism. We established this for a patient who initially, after a psychic trauma, manifested a strongly reduced glucose metabolism in his brain (particularly in memory processing regions) (Markowitsch et al., 1998) and who, after successful treatment of his amnesia,

also demonstrated a normal glucose metabolism (Markowitsch et al., 2000a).

These results support the view that organic and functional (psychogenic) amnesias are two sides of the same coin (Markowitsch, 1996). Both kinds of phenomena may derive from a common brain mechanism leading to blockade, disruption, or disconnection mechanisms affecting the processes of memory and disintegrating widespread memory networks in the brain. This disintegration may be a consequence of “mechanical alterations” in the brain of organic amnesics and may be a consequence of biochemical alterations in the brain of psychogenic amnesics. For these, such processes may be induced during autobiographical information processing by desynchronization memory patterns, resulting in the reduction of discomfort for the subject. In the widest exegesis, both forms of amnesia may be viewed as related to the patient's wish to avoid confrontation with his or her biography.

## Acknowledgments

The work reported herein was supported by the German Research Council (DFG; Ma 795), by the VolkswagenStiftung (II/77036), and by the Köhler-Stiftung.

## References

- Anderson, C.M., Teicher, M.H., Polcari, A., Renshaw, P.F., 2002. Abnormal T2 relaxation time in the cerebellar vermis of adults sexually abused in childhood: potential role of the vermis in stress-enhanced risk for drug abuse. *Psychoneuroendocrinology* 27, 231–244.
- Baddeley, A., 2000. Short-term and working memory, in: Tulving, E., Craik, F.I.M. (Eds.), *The Oxford handbook of memory*, Oxford Univ. Press, New York, pp. 77–92.
- Brand, M., Markowitsch, H.J., 2003. The bottleneck structures implicated in memory processing, in: Kluwe, R.H., Lüer, G., Rösler, F. (Eds.), *Learning and memory*, Birkhäuser, Basel, pp. 171–184.
- Bremner, J.D., 2001. Hypotheses and controversies related to effects of stress on the hippocampus: an argument for stress-induced damage to the hippocampus in patients with posttraumatic stress disorder. *Hippocampus* 11, 75–81.
- Bremner, J.D., 2002. *Does stress damage the brain?* Norton, New York.
- Brewin, C.R., 2001. Memory processes in post-traumatic stress disorder. *Int. Rev. Psychiatry* 13, 159–163.
- Costello, A., Fletcher, P.C., Dolan, R.J., Frith, C.D., Shallice, T., 1998. The origins of forgetting in a case of isolated retrograde amnesia following a haemorrhage: evidence from functional imaging. *Neurocase* 4, 437–446.
- Cowan, N., 1984. On short and long auditory stores. *Psychol. Bull.* 96, 341–370.
- Cowan, N., 2000. The magical number 4 in short-term memory: a reconsideration of mental storage capacity. *Behav. Brain Sci.* 24, 87–185.
- de Kloet, E.R., Oitzl, M.S., Joëls, M., 1999. Stress and cognition: are corticosteroids good or bad guys? *Trends Neurosci.* 10, 422–426.
- De Renzi, E., Lucchelli, F., Muggia, S., Spinnler, H., 1997. Is memory loss without anatomical damage tantamount to a psychogenic deficit? The case of pure retrograde amnesia. *Neuropsychologia* 35, 781–794.
- Fink, G.R., Markowitsch, H.J., Reinkemeier, M., Bruckbauer, T., Kessler, J., Heiss, W.-D., 1996. Cerebral representation of one's own past: neural networks involved in autobiographical memory. *J. Neurosci.* 16, 4275–4282.
- Halligan, P.W., David, A.S., 2001. Cognitive neuropsychiatry: towards a scientific psychopathology. *Nat. Rev. Neurosci.* 2, 209–215.
- Highley, J.R., Walker, M.A., Esiri, M.M., Crow, T.J., Harrison, P.J., 2002. Asymmetry of the uncinate fasciculus: a post-mortem study of normal subjects and patients with schizophrenia. *Cereb. Cortex* 12, 1218–1224.
- Iverson, G.L., Franzen, M.D., 1996. Using multiple objective memory procedures to detect simulated malingering. *J. Clin. Exp. Neuropsychol.* 18, 38–51.
- Kim, J.J., Yoon, K.S., 1998. Stress: metaplastic effects in the hippocampus. *Trends Neurosci.* 21, 505–509.
- Kritchevsky, M., Zouzounis, J., Squire, L.R., 1997. Transient global amnesia and functional retrograde amnesia: contrasting examples of episodic memory loss. *Philos. Trans. R. Soc. London B Biol. Sci.* 352, 1747–1754.
- Kroll, N., Markowitsch, H.J., Knight, R., von Cramon, D.Y., 1997. Retrieval of old memories—the temporo-frontal hypothesis. *Brain* 120, 1377–1399.
- Leng, N.R.C., Parkin, A.J., 1995. The detection of exaggerated or simulated memory disorder by neuropsychological methods. *J. Psychosom. Res.* 39, 767–776.
- LeDoux, J., 2000. Cognitive–emotional interactions: listen to the brain, in: Lane, R., Nadel, L. (Eds.), *Cognitive neuroscience of emotion*, Oxford Univ. Press, New York, pp. 129–155.
- Lucchelli, F., Spinnler, H., 2002. The “psychogenic” versus “organic” conundrum of pure retrograde amnesia: is it still worth pursuing? *Cortex* 38, 665–669.
- Markowitsch, H.J., 1992. *Intellectual functions and the brain: an historical perspective*. Hogrefe & Huber, Toronto.
- Markowitsch, H.J., 1996. Organic and psychogenic retrograde amnesia: two sides of the same coin? *Neurocase* 2, 357–371.
- Markowitsch, H.J., 1998. The mnestic block syndrome: environmentally induced amnesia. *Neurol. Psychiatr. Brain Res.* 6, 73–80.
- Markowitsch, H.J., 1999. Functional neuroimaging correlates of functional amnesia. *Memory* 7, 561–583.
- Markowitsch, H.J., 2000a. Repressed memories, in: Tulving, E. (Ed.), *Memory, consciousness, and the brain: the Tallinn conference*, Psychol. Press, Philadelphia, pp. 319–330.
- Markowitsch, H.J., 2000b. Functional amnesia: the mnestic block syndrome. *Rev. Neuropsychol.* 10, 175–198.
- Markowitsch, H.J., 2002a. Neuropsychology of memory: organic and psychic disorders, and functional imaging correlates, in: Yamadori, A., Kawashima, R., Fuji, T., Suzuki, K. (Eds.), *Frontiers of human memory*, Tohoku Univ. Press, Sendai, pp. 297–315.
- Markowitsch, H.J., 2002b. Functional retrograde amnesia—mnestic block syndrome. *Cortex* 38, 651–654.
- Markowitsch, H.J., 2003. The neuroanatomy of memory, in: Halligan, P., Wade, P. (Eds.), *The effectiveness of rehabilitation for cognitive deficits*, Oxford Univ. Press, Oxford (in press).
- Markowitsch, H.J., Calabrese, P., Haupts, M., Durwen, H.F., Liess, J., Gehlen, W., 1993. Searching for the anatomical basis of retrograde amnesia. *J. Clin. Exp. Neuropsychol.* 15, 947–967.
- Markowitsch, H.J., Fink, G.R., Thöne, A., Kessler, J., Heiss, W.-D., 1997a. A PET study of persistent psychogenic amnesia covering the whole life span. *Cognit. Neuropsychiatry* 2, 135–158.
- Markowitsch, H.J., Kessler, J., Fröhlich, L., Schneider, B., Maurer, K., 1999a. Mnestic block syndrome. *Cortex* 35, 219–230.
- Markowitsch, H.J., Kessler, J., Kalbe, E., Herholz, K., 1999b. Functional amnesia and memory consolidation: a case of severe and persistent anterograde amnesia with rapid forgetting following whiplash injury. *Neurocase* 5, 189–200.
- Markowitsch, H.J., Kessler, J., Van der Ven, C., Weber-Luxemburger, G., Albers, M., Heiss, W.D., 1998. Psychic trauma causing grossly reduced brain metabolism and cognitive deterioration. *Neuropsychologia* 36, 77–82.
- Markowitsch, H.J., Kessler, J., Weber-Luxemburger, G., Van der Ven, C., Albers, M., Heiss, W.D., 2000a. Neuroimaging and behavioral correlates of recovery from mnestic block syndrome and other cognitive deteriorations. *Neuropsychiatr. Neuropsychol. Behav. Neurol.* 13, 60–66.
- Markowitsch, H.J., Thiel, A., Kessler, J., von Stockhausen, H.-M., Heiss, W.-D., 1997b. Ecphorizing semi-conscious information via the right temporopolar cortex—a PET study. *Neurocase* 3, 445–449.
- Markowitsch, H.J., Thiel, A., Reinkemeier, M., Kessler, J., Koyuncu, A., Heiss, W.-D., 2000b. Right amygdalar and temporo-frontal activation during autobiographic, but not during fictitious memory retrieval. *Behav. Neurol.* 12, 181–190.
- McEwen, B.S., 1999. Stress and hippocampal plasticity. *Annu. Rev. Neurosci.* 22, 105–122.
- McEwen, B.S., 2000. The neurobiology of stress: from serendipity to clinical relevance. *Brain Res.* 886, 172–189.
- McGaugh, J.L., 2000. Memory—a century of consolidation. *Science* 287, 248–251.
- Meyer, U., van Kampen, M., Isovich, E., Flüggé, G., Fuchs, E., 2001. Chronic psychosocial stress regulates the expression of both GR and MR mRNA in the hippocampal formation of tree shrews. *Hippocampus* 11, 329–336.

- Miller, G.A., 1956. The magical number seven plus minus two: some limits on our capacity for processing information. *Psychol. Rev.* 63, 244–257.
- Nam, Y.J., Stover, T., Hartman, S.S., Altschuler, R.A., 2000. Upregulation of glial cell line-derived neurotrophic factor (GDNF) in the rat following cochlea noise. *Hearing Res.* 146, 1–8.
- O'Brien, J.T., 1997. The 'glucocorticoid cascade' hypothesis in man. *Br. J. Psychiatry* 170, 199–201.
- Piefke, M., Weiss, P.H., Zilles, K., Markowitsch, H.J., Fink, G.R., 2003. Differential remoteness and emotional tone modulate the neural correlates of autobiographical memory. *Brain* 126, 850–868.
- Porter, N.M., Landfield, P.W., 1998. Stress hormones and brain aging: adding injury to insult? *Nat. Neurosci.* 1, 3–4.
- Schore, A.N., 2002. Dysregulation of the right brain: a fundamental mechanism of traumatic attachment and the psychopathogenesis of posttraumatic stress disorder. *Aust. N. Z. J. Psychiatry* 36, 9–30.
- Thomas-Antérion, C., Truche, A., 1998. Stress, anxiété et mémoire. *Rev. Géiatr.* 23, 723–728.
- Tombaugh, T.N., 1996. Test of memory malingering (TOMM). Multi Health Systems, New York.
- Yasuno, F., Nishikawa, T., Nakagawa, Y., Ikejiri, Y., Tokunaga, H., Mizuta, I., et al., 2000. Functional anatomical study of psychogenic amnesia. *Psychiatry Res. Neuroimaging Sect.* 99, 43–57.
- Yoshino, R., 1993. Magical numbers of human short-term memory: efficient designs of biological memory systems? *Behaviormetrika* 20, 171–186.