

Orbitofrontal, amygdala and hippocampal volumes in teenagers with first-presentation borderline personality disorder

Andrew M. Chanen^{a,b,*}, Dennis Velakoulis^c, Kate Carison^a, Karen Gaunson^a,
Stephen J. Wood^{c,d}, Hok Pan Yuen^a, Murat Yücel^{a,c}, Henry J. Jackson^{a,e},
Patrick D. McGorry^{a,b}, Christos Pantelis^c

^aORYGEN Research Centre, Department of Psychiatry, The University of Melbourne, Melbourne, Australia

^bORYGEN Youth Health, Northwestern Mental Health, Melbourne, Australia

^cMelbourne Neuropsychiatry Centre, Department of Psychiatry, The University of Melbourne and Melbourne Health, Melbourne, Australia

^dBrain Research Institute, Austin and Repatriation Medical Centre, Melbourne, Australia

^eSchool of Behavioural Sciences, The University of Melbourne, Melbourne, Australia

Received 13 April 2007; received in revised form 3 July 2007; accepted 26 August 2007

Abstract

It is not known whether the fronto-limbic volume reductions found in adults with established borderline personality disorder (BPD) are present early in the disorder. The aim of the study was to investigate orbitofrontal cortex (OFC), hippocampal and amygdala volumes in a first-presentation teenage BPD sample with minimal exposure to treatment. Groups of 20 BPD patients and 20 healthy control participants underwent magnetic resonance imaging. Hippocampal, amygdala, OFC and whole brain volumes were estimated and compared between the two groups. Analysis of variance revealed reversal of the normal (right > left) asymmetry of OFC grey matter volume in the BPD group, reflecting right-sided OFC grey matter loss in the BPD group compared with control participants. No significant differences were found for amygdala or hippocampal volumes comparing BPD with control participants. We identified OFC but not hippocampal or amygdala volumetric differences early in the course of BPD. Hippocampal and amygdala volume reductions observed in adult BPD samples might develop during the course of the disorder, although longitudinal studies are needed to examine this.

© 2007 Elsevier Ireland Ltd. All rights reserved.

Keywords: MRI; Laterality; Adolescence

1. Introduction

Structural magnetic resonance imaging (MRI) findings in adults with borderline personality disorder (BPD) (reviewed in [Schmahl and Bremner, 2006](#)) include

volume reductions in the amygdala ([Driessen et al., 2000](#); [Rusch et al., 2003](#); [Schmahl et al., 2003](#); [Tebartz van Elst et al., 2003](#)), hippocampus ([Driessen et al., 2000](#); [Schmahl et al., 2003](#); [Tebartz van Elst et al., 2003](#); [Brambilla et al., 2004](#); [Irlle et al., 2005](#)), orbitofrontal cortex (OFC) ([Tebartz van Elst et al., 2003](#)), frontal lobes ([Lyoo et al., 1998](#)) and cingulate cortex ([Tebartz van Elst et al., 2003](#); [Hazlett et al., 2005](#)). However, it is unclear whether these findings are associated with a vulnerability to BPD itself, severity or duration of BPD,

* Corresponding author. ORYGEN Research Centre, Locked Bag 10, Parkville, Victoria, Australia 3052. Tel.: +61 3 9342 2800; fax: +61 3 9387 3003.

E-mail address: achanen@unimelb.edu.au (A.M. Chanen).

treatment or other factors, such as cumulative traumatic events, associated lifestyle factors or the co-occurrence or duration of common mental disorders. Studies of samples earlier in the course of BPD reduce the effects of duration of illness factors upon brain morphology. This is the first study to measure hippocampal, amygdala and OFC volumes in teenagers with first-presentation BPD in order to ascertain whether the changes found in previous studies of adults pre-date the full expression of BPD. In addition, we explored how co-occurring clinical characteristics were associated with brain morphology.

2. Methods

2.1. Participants

Twenty patients meeting Structured Clinical Interview for DSM-IV Axis II Disorders (SCID-II) (First et al., 1997) criteria for BPD were recruited from a specialized early intervention program for BPD at ORYGEN Youth Health in Melbourne, Australia. They had minimal exposure to psychiatric interventions and had never received specific treatment for BPD. Sixteen patients (80%) had a lifetime history of non-specialized prior counseling or psychotherapy (median=6 sessions, range=1–140). One (5%) patient had a lifetime history of 78 weeks of antidepressant medication for treatment of depression. Five (25%) patients had a lifetime history of one psychiatric admission each. Three of these five admissions were for 1 day, one was for 3 days, and one was for 34 days. Nine scans (45%) were completed at entry into the program, seven scans (35%) around the 6-month assessment, and four scans (20%) around the 12-month assessment. The assessment closest to their MRI scan date was used for 'state' measures, such as axis I diagnoses. The median interval between assessment and scan dates was 35.5 days (range=0–102).

BPD participants satisfied, on average, 6.0 DSM-IV BPD criteria (S.D.=0.9) on entry to the clinic and 5.3 criteria at the time of scanning (S.D.=1.6). Age at MRI scan, sex and diagnostic data are shown in Table 1.

Interview data on lifetime history of abuse or trauma were available for 19 participants. Ten participants (50%) denied any experience of abuse or trauma. Of the nine participants with experience of abuse or trauma, six (30%) reported physical abuse, five (25%) reported sexual abuse, and five (25%) reported emotional abuse.

At the time of scanning, 17 participants (85%) were unmedicated, one (5%) was taking citalopram, one (5%) was taking venlafaxine, and one (5%) was on both sertraline and methadone maintenance therapy.

Table 1
Borderline personality disorder participant characteristics

Participant number	Age (years)	Sex	Axis I diagnoses	Axis II diagnoses
1.	19.2	F		BPD
2.	18.2	F	Alcohol dependence	BPD
3.	18.0	F		BPD, PAPD, DPD
4.	16.8	M	Cannabis dependence	BPD, APD
5.	18.9	F	CD	BPD, ASPD, DPD
6.	17.4	F	DD, social phobia	BPD, ASPD
7.	17.2	M	ODD, cannabis dependence	BPD, PAPD
8.	15.6	F	CD	BPD, PAPD
9.	18.2	F	ODD	BPD, DPD, ASPD
10.	15.4	F	MDD, DD, specific phobia, GAD	BPD, DPD, PAPD
11.	17.2	F	MDD, panic disorder with agoraphobia, PTSD, ED NOS	BPD, APD, DPD
12.	17.5	M	Specific phobia	BPD
13.	18.2	F		BPD, APD, DPD
14.	17.6	F	CD, Bipolar I, panic disorder without agoraphobia	BPD, PAPD, DPD, PPD
15.	18.2	M	CD, anxiety disorder NOS, alcohol abuse, cannabis dependence	BPD, ASPD
16.	16.2	M	CD, anxiety disorder NOS	BPD
17.	17.5	F		BPD
18.	17.4	F	CD, MDD, panic disorder without agoraphobia, cannabis dependence	BPD, ASPD
19.	16.2	F	CD, MDD, cannabis dependence	BPD
20.	16.0	F	CD, specific phobia	BPD, PAPD, ASPD

F — female; M — male; CD — conduct disorder; ODD — oppositional defiant disorder; MDD — major depressive disorder; DD — dysthymic disorder; GAD — generalized anxiety disorder; ED — eating disorder; NOS — not otherwise specified; BPD — borderline personality disorder; ASPD — antisocial personality disorder; PAPD — passive-aggressive personality disorder; DPD — depressive personality disorder; APD — avoidant personality disorder, PPD — paranoid personality disorder.

Twenty control participants were drawn from a pool of healthy volunteers, carefully screened for no personal or family history of psychiatric illness, substance abuse or neurological disorder. BPD screens were performed by a psychiatrist (DV), clinical neuropsychologist and an experienced graduate research assistant trained in clinical diagnosis, using a checklist derived from the SCID-II. Control participants were matched exactly by sex and as closely as possible on a group basis on the other variables in Table 2.

All participants were physically healthy, based upon medical history. Potential BPD participants were excluded

from the study if they had a schizophrenia spectrum or affective psychotic disorder, anorexia nervosa, current alcohol dependence of 2 months or greater duration or if they had a history of head injury, loss of consciousness for 10 min or more, seizures, thyroid disorder or other significant medical illness.

The study was approved by the local Research and Ethics Committees. After complete description of the study to the participants, written informed consent was obtained from participants or from a parent or guardian, where appropriate. Patients, but not control participants, were remunerated AU\$50.

2.2. Measures

Axis I diagnoses were made with the Structured Clinical Interview for DSM-IV patient version (SCID-I/P (First et al., 1996)), supplemented by the Kiddie-SADS-Present and Lifetime Version (K-SADS-PL) Disruptive Behavior Disorders section (Kaufman et al., 1997). Axis II diagnoses were made with the SCID-II (First et al., 1997). A PD feature was scored positive if it was present for 2 years and did not occur exclusively in the context of an axis I disorder.

BPD participants aged below 18 years completed the Youth Self-Report (YSR) (Achenbach, 1991) and those 18 years and above completed the Young Adult Self-Report (YASR (Achenbach, 1997)). Mean scores for the YSR and YASR internalizing and externalizing subscales were calculated to ensure comparability between the instruments.

Number of parasuicidal episodes (intentional, non-fatal self-injury, regardless of the intent to die) and number of violent episodes (attacks against people, animals or property) over the previous 6 months, along with lifetime exposure to trauma (age of onset, number and duration of episodes of physical, sexual or emotional abuse), were all assessed by semi-structured interview, developed by the investigators (available upon request).

2.3. MRI acquisition and procedures

All participants and controls were scanned using the same GE Signa 1.5 T scanner (GE, Milwaukee, WI) at Royal Melbourne Hospital. A three-dimensional volumetric spoiled gradient recalled echo in the steady state sequence (SPGR) generated 124 contiguous 1.5-mm coronal slices. Imaging parameters were TE=3.3 ms, TR=14.3 ms, flip angle=30°, matrix size=256×256, FOV=24×24 cm, voxel dimension=0.938×0.938×1.5 mm.

Table 2
Sample characteristics

	BPD group (n=20)	Control group (n=20)
Age (years)	17.3±1.1	19.0±2.2
Height (cm)	166.2±11.5	168.2±10.2
Handedness	18 right (90), 1 left (5), 1 mixed (5)	18 right (90), 2 left (10)
Female sex	15 (75)	15 (75)

Data are given as mean±S.D. or number (percentage). BPD indicates borderline personality disorder.

The scanner was calibrated fortnightly using the same proprietary phantom to ensure stability and accuracy of the measurements. MRI data were transferred from DAT tape to a SGI 02 workstation and coded to ensure patient confidentiality and blind rating of data.

The methods for estimation of hippocampal, amygdala, orbitofrontal cortex, whole brain and intracranial volumes have been previously described (Riffkin et al., 2005; Velakoulis et al., 2006). Structural brain analyses were undertaken using ANALYZE (Robb, 2001; whole brain, intracranial volume, hippocampus, amygdala) and Functional Automated Segmentation Tool (FAST; Zhang et al., 2001; orbitofrontal cortex).

2.3.1. Intracranial volumes

Intracranial volumes (ICV) were estimated from a sagittal reformat of the original 3D dataset (Eritaia et al., 2000). The major anatomical boundary was the dura mater below the inner table and generally visible as a white line. Where the dura mater was not visible, the cerebral contour was outlined. Other landmarks were the undersurfaces of the frontal lobe, the dorsum sellae, clivus, and at the craniovertebral junction the attachment of the dura to the anterior cutting across to the posterior arch of C1. Inter- and intra-rater intraclass correlation coefficients (ICCs) were 0.99 for 10 randomly selected volumes.

2.3.2. Whole brain volumes

Whole brain volumes were estimated using BET (Brain Extraction Tool) (Smith, 2002) to separate brain from non-brain tissue. Following brain/non-brain segmentation, tissue-type segmentation was performed using FAST ((Zhang et al., 2001; whole brain volumes), that is, classification of each voxel into grey, white, or CSF (cerebro-spinal fluid). For the purposes of the current study, only grey matter and white matter were used in the estimate of whole brain volumes.

2.3.3. Orbitofrontal cortex

Posterior boundary: the transverse slice one slice anterior to the junction of the olfactory sulcus and the

anterior perforating substance. *Superior boundary*: the anterior commissure–posterior commissure line (AC–PC line) was chosen as the superior boundary. *Anterior border*: the edge of the brain where it interfaced with CSF. *Inferolateral boundary*: defined by a line manually traced on each of the approximately 60 slices per image to separate the temporal lobe, facial bones and skull from the OFC. *Medial boundary*: defined in each hemisphere by the longitudinal fissure. Within each hemisphere, our method included both the medial (gyrus rectus) and lateral aspects of the OFC in this measurement. Left and right hemispheres were then separated, and the volumes of both hemispheres were processed using FAST (Zhang et al., 2001) to automatically segment the regions into grey and white tissue types. Two operators (KG and JR) rated 10 random images unrelated to the current study. Intra-rater and inter-rater reliabilities were obtained on the combined left and right total OFC volumes. The ICC was greater than 0.95 for all measures.

2.3.4. Hippocampal volumes

Hippocampal volumes were estimated using a manual tracing technique and defined anatomical criteria (Cook et al., 1992). Hippocampal boundaries were as follows: Posterior — slice with greatest length of continuous fornix; medial — open end of the hippocampal fissure posteriorly, uncus fissure in the hippocampal body and medial aspect of ambient gyrus anteriorly; lateral — temporal horn of lateral ventricle; inferior — white matter inferior to the hippocampus; superior — superior border of hippocampus; anteriorly — alveus was used to differentiate hippocampal head from amygdala. The anterior border was the most difficult to identify consistently and was aided by moving between slices before and after the index slice. Inter- and intra-rater reliabilities were assessed by ICC. Inter-rater ICC reliabilities were 0.89 (right) and 0.77 (left). Intra-rater ICC reliabilities were 0.94 (right) and 0.85 (left).

2.3.5. Amygdala volumes

The method used to estimate amygdala volumes was adapted from a previously described method (Convit et al., 1999; Velakoulis et al., 2006). Amygdala boundaries were Posterior: appearance of amygdala grey matter above the temporal horn. Superior–lateral: the thin strip of white matter that separates the amygdala from the claustrum and the tail of the caudate. Medial: the angular bundle, which separates the amygdala from the entorhinal cortex. Superior–medial: the semilunar gyrus. Inferior: the hippocampus. Inferior–lateral: the temporal

lobe white matter and the extension of the temporal horn. Anterior: slice anterior to the appearance of the optic chiasm. Inter-rater ICC reliabilities were 0.70 (right) and 0.79 (left). Intra-rater ICC reliabilities were 0.87 (right) and 0.88 (left).

2.4. Statistical analysis

Statistical analyses were conducted using the Statistical Package for the Social Sciences (SPSS), version 12 (Chicago, IL). Analysis of covariance, with height as the covariate, was carried out to compare whole brain volume (WBV) and intracranial volume (ICV) in the BPD and healthy control groups.

For the hippocampal and amygdala volume measures, multivariate analysis of variance (MANOVA) was carried out on the volume measures with group (BPD versus control) and gender as between-subject factors and side (left versus right) as the within-subject factor. WBV and age were used as covariates. The same procedure was used for the OFC volume measures, but both side and tissue (grey versus white) were used as within-subject factors.

In order to examine possible differences within the BPD group caused by temporal or mental state factors, the MANOVAs carried out on the volume measures, above, were repeated, where group was in turn: 1) BPD participants with mood and/or anxiety disorder ($n=10$) versus BPD participants without mood and/or anxiety disorder ($n=10$), 2) BPD participants with disruptive behavior disorders ($n=10$) versus BPD participants without disruptive behavior disorders ($n=10$), 3) BPD participants scanned at baseline ($n=9$) versus BPD participants scanned at 6 or 12 months after entry to the treatment program ($n=11$), and 4) BPD participants reporting prior exposure to trauma ($n=9$) versus BPD participants not reporting prior exposure to trauma ($n=10$).

Analyses were also conducted to examine the relationships between structural volumes and the clinical features of BPD. Partial correlations, controlling for age and WBV, were calculated between each volume measure (right and left OFC grey matter, hippocampi and amygdalae) and each of the nine BPD criteria, along with some ‘state’ variables (internalizing and externalizing scores on the YSR/YASR, along with number of violent episodes and number of episodes of DSH in the past 6 months) that might be expected to have a relationship with these structures. Although many correlations were examined, correction for multiple testing was not performed because we were not carrying out joint hypothesis testing.

Finally, in order to assess whether ICV was influential as a covariate, all analyses involving WBV as a covariate were repeated, substituting ICV. For all analyses, the pattern of results was identical using WBV or ICV. Therefore, only the analyses using WBV are reported.

3. Results

3.1. Volumetric findings

The raw data for all structural volume measures are displayed in Table 3. Analysis of covariance, using height as the covariate, did not reveal any significant differences between the BPD and healthy control groups on measures of WBV or ICV (all $P > 0.5$).

MANOVA on the four OFC volume measures revealed a significant group by side by region interaction ($F_{1,36} = 4.68$, $P = 0.037$). Further pairwise tests (see Table 4) revealed a significant difference between left and right OFC grey matter for normal controls ($t_{19} = -2.89$, $P = 0.009$). However, this asymmetry was not found between the left and right OFC grey matter for BPD participants ($t_{19} = 1.59$, $P > 0.1$). The asymmetry index ($100 \times (L - R) / [0.5 \times (L + R)]$) (Pujol et al., 2002) was calculated for orbitofrontal grey matter and white matter. Analyses using the general linear model, with group (BPD versus normal) and gender as factors and age and WBV as covariates, revealed a significant group difference for orbitofrontal grey matter ($F_{1,35} = 8.62$, $P = 0.006$). The estimated difference (BPD minus normal; see Fig. 1) after adjusting for age, WBV and gender was 7.8 (SE 2.7; 95% CI 2.4, 13.2). Inspection of the raw data in Table 3

Table 3
MRI volume measurements in borderline personality disorder and healthy control participants

Volume	BPD ^a	Control ^a
	(n=20)	(n=20)
Intra-cranial volume (cm ³)	1370.2±104.1	1362.8±140.6
Whole brain volume (cm ³)	1218.8±99.5	1208.1±128.3
Left orbitofrontal grey matter	16,382.5±2967.5	16,593.8±3650.2
Right orbitofrontal grey matter	15,932.9±2845.3	17,324.1±3847.3
Left orbitofrontal white matter	9343.9±1739.0	9848.8±2328.2
Right orbitofrontal white matter	9286.5±2125.8	9952.9±2400.2
Left hippocampus	2819.8±275.2	2690.1±297.6
Right hippocampus	2980.4±383.2	2842.5±189.2
Left amygdala	997.0±118.7	1023.2±218.9
Right amygdala	1007.1±169.5	1044.9±241.5

Data are given as mean±S.D. volume (mm³ unless stated).

BPD indicates borderline personality disorder.

^a Raw data, not adjusted for age, whole brain volume or gender.

Table 4

Pairwise comparisons (LSD test) for OFC volume measurements in borderline personality disorder and healthy control participants

		BPD minus normal ^a			
		t-value (df=35)	P-value	Estimated difference (mm ³)	95% CI for the difference
BPD vs. normal	Left grey	-0.26	0.80	-274.04	(-2398.91, 1850.83)
	Left white	-0.53	0.60	-328.70	(-1578.09, 920.69)
	Right grey	-1.40	0.17	-1612.58	(-3944.55, 719.40)
	Right white	-0.64	0.53	-460.86	(-1917.21, 995.50)
		Left minus right			
		t-value (df=19)	P-value	Estimated difference (mm ³)	95% CI for the difference
Left vs. Right	Grey normal	-2.89	0.009	-730.31	(-1259.49, -201.12)
	Grey BPD	1.59	0.13	449.55	(-142.75, 1041.85)
	White normal	-0.64	0.53	-104.20	(-443.09, 234.69)
	White BPD	0.23	0.82	57.34	(-455.82, 570.49)

BPD indicates borderline personality disorder.

CI indicates confidence interval.

^a Adjusted for age, whole brain volume and gender.

and the estimated differences in Table 4 reveals that the reversal of normal asymmetry in the BPD group reflects a reduction in right OFC grey matter volume in BPD compared to controls.

For the hippocampal volumes, there were no significant differences ($P > 0.05$) between the left and right sides or between BPD and control participants. There was a non-significant trend for a group by gender by side interaction ($F_{1,36} = 3.34$, $P = 0.076$), with larger right hippocampi observed in males with BPD. This was not pursued further due to the small sample size.

For the amygdala volumes, there were no significant differences between the left and right sides or between BPD patients and normal controls ($P > 0.05$). However, there was a significant group by gender interaction ($F_{1,34} = 9.57$, $P = 0.004$). Further pairwise tests revealed smaller amygdalae in males with BPD bilaterally (left: $t_{34} = -3.29$, $P = 0.002$; right: $t_{34} = -2.40$, $P = 0.022$). This was not pursued further due to the small sample size.

In order to examine possible differences within the BPD group caused by temporal or mental state factors, the MANOVAs carried out on the volume measures (OFC, hippocampus and amygdala), above, were repeated, where group was in turn: 1) mood and/or anxiety

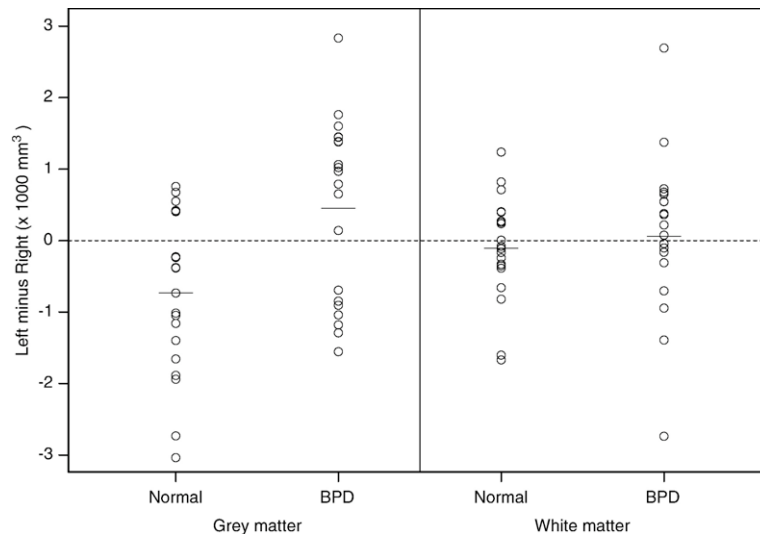


Fig. 1. Plot of the difference in OFC grey and white matter volumes between left and right sides for each participant. Horizontal line denotes the mean difference.

disorder (yes/no), 2) disruptive behavior disorders (yes/no), 3) MRI scan at baseline versus MRI after entry to the treatment program, and 4) self-reported exposure to trauma (yes/no). For each comparison, no significant group differences were found.

3.2. Relationship to features of BPD and other clinical variables

Partial correlations, controlling for age and WBV, were calculated between each volume measure (right and left OFC grey matter, hippocampi and amygdalae) and the total SCID-II BPD score, SCID-II scores for each of the nine DSM-IV BPD criteria, along with the number of violent episodes in the previous 6 months, the number of episodes of DSH in the previous 6 months, internalizing score and externalizing score. For OFC grey matter volumes, these were calculated for males and females together. However, as there was a gender interaction for amygdala volumes and a trend for the same in regard to hippocampal volumes, partial correlations for hippocampi and amygdalae were only calculated for females.

No statistically significant correlations ($P > 0.05$) were found for right or left OFC grey matter volumes with any of the clinical variables. For females with BPD, significant correlations were found between the right amygdala volume and 1) SCID-II total BPD score ($r = -0.613$, $P = 0.026$), 2) SCID-II impulsivity ($r = -0.579$, $P = 0.038$), 3) SCID-II inappropriate anger ($r = -0.639$, $P = 0.019$), 4) YSR/YASR internalizing ($r = -0.617$, $P = 0.025$) and 5) YSR/YASR externalizing ($r = -0.739$, $P = 0.004$). No

other statistically significant correlations ($P > 0.05$) were found.

4. Discussion

Three main findings emerge from this unique study of teenagers with first-presentation BPD. Firstly, there is a reversal of the normal (right > left) asymmetry of OFC grey matter in the BPD group, reflecting right-sided OFC grey matter loss in the BPD group that is not related to gender, the clinical features of BPD or other mental state phenomena. Secondly, hippocampal and amygdala volumes are not reduced in BPD participants compared with healthy controls. Thirdly, in females with BPD, large and significant correlations are observed between the right amygdala volume and some clinical features of BPD and measures of 'state' psychopathology. Given the findings of frontal and medial temporal volume reduction in adults with BPD, these findings in adolescents suggest that OFC changes are present early in the disorder and that medial temporal lobe volume changes might become apparent as a function of time or severity of BPD.

The reduction of right OFC grey matter volume in BPD participants is consistent with previous structural imaging studies of the frontal lobes in adults with BPD (Lyo et al., 1998; Tebartz van Elst et al., 2003), along with functional imaging at baseline (Goyer et al., 1994; De la Fuente et al., 1997; Soloff et al., 2003), using pharmacological probes (Soloff et al., 2000; Leyton et al., 2001) and scripts describing personal traumatic abuse events (Schmahl et al., 2004). It is also consistent with a neuropsychological investigation showing increased

impulsivity in BPD and specifically implicating the OFC in BPD phenomenology (Berlin et al., 2005). Our finding of right-sided OFC changes, in contrast to left-sided OFC change in a previous study (Tebartz van Elst et al., 2003), might reflect specialization of the functions of the OFC but might equally reflect a lack of statistical power to detect changes bilaterally. Also, the lack of any association between right or left OFC grey matter volume and the clinical features of BPD or current psychopathology raises questions about the possible clinical significance of the volume changes found in the OFC. As structural volume and functioning might not be clearly related, functional and neurochemical imaging techniques or neuropsychological methods might be better suited to elucidate any potential relationship.

Our OFC findings are also consistent with studies of the putative BPD endophenotype of impulsive aggression (Siever et al., 2002) and with the clinical lesion literature. One positron emission tomography study in impulsive aggressive adults found a blunted response to serotonergic probes in the OFC and cingulate cortex (New et al., 2002) and another found evidence of a dysfunctional prefrontal circuit (Best et al., 2002). Studies of childhood PFC damage (Eslinger et al., 2004) suggest a distinctive developmental course for early orbital–polar prefrontal lesions comprising deficits in social cognition, personality and emotion (among others) consistent with many of the features of BPD. Also, six BPD participants in our study met diagnostic criteria for conduct disorder, which might be a precursor to antisocial personality disorder (ASPD), a syndrome with substantial overlap with BPD. Deficits in PFC grey matter volume have also been found in ASPD (Raine et al., 2000). Our analyses comparing the BPD participants with disruptive behavior disorders to those without did not reveal any differences in OFC or other volume measures.

Our hippocampal and amygdala volume findings stand in marked contrast to the growing structural imaging literature in adults with BPD (Driessen et al., 2000; Rusch et al., 2003; Schmahl et al., 2003; Tebartz van Elst et al., 2003; Brambilla et al., 2004; Irle et al., 2005), identifying medial temporal lobe structural volume reductions. However, despite the weight of evidence, two recent MRI studies (Brambilla et al., 2004; Zetzsche et al., 2006) have failed to find amygdala volume reduction in adults with BPD. One of these (Zetzsche et al., 2006) found amygdala volume enlargement in BPD participants with co-occurring major depression, compared to BPD participants without depression, along with a positive correlation between amygdala volume and the amount of depressive symptomatology. Comparisons within our BPD sample

did not replicate this finding. Moreover, we found a large inverse correlation between right amygdala volume and YSR/YASR internalizing score (which includes depressive and anxiety symptoms).

Our amygdala and hippocampal findings might also have been predicted given a CT scan study of teenagers which found no difference in the ventricular-brain ratios of BPD patients compared to normal controls (Schulz et al., 1983) and given studies of adolescent depression (Rosso et al., 2005) and PTSD (De Bellis et al., 2001), which have failed to find the hippocampal volume loss observed in adults with these conditions. It is plausible that the changes observed in adults with BPD might be acquired, either as a consequence of the changes in the OFC, via its limbic connections or through the experiencing of repeated episodes of mental state pathology, such as depression or PTSD. This latter hypothesis is supported by our finding that, in females with BPD, smaller right amygdala volume was associated with higher levels of internalizing and externalizing pathology.

Comparisons within the BPD group did not identify differences for any structural volumes in those BPD participants with prior exposure to trauma compared to those without. While exposure to trauma might account for the hippocampal volume loss identified in adults with BPD, amygdala volume loss is unlikely to be explained by this mechanism (Schmahl and Bremner, 2006).

The large inverse correlations found in female BPD participants between the right amygdala and some clinical variables are striking. Smaller right amygdalae were associated with higher BPD scores, particularly higher levels of impulsivity and inappropriate anger, along with higher levels of internalizing and externalizing psychopathology. These findings are consistent with the role of the amygdala in aggressive and impulsive behaviors, and the lateralization of these findings is consistent with our OFC finding. These data also support the hypothesis that either female BPD participants with smaller amygdalae (and more severe psychopathology) progress to adult BPD or amygdala volume reduction might be secondary to recurrent or chronic ‘state’ psychopathology. As the relationship between brain structure and function is indirect, elucidation of these processes will require longitudinal studies utilizing structural, functional and neurochemical imaging techniques.

4.1. Strengths

The strengths of this study include using a novel sample of young people diagnosed for the first time with BPD and with minimal exposure to psychiatric

interventions. The mean age of our BPD patients was 10 years less than previously published MRI studies of BPD, in which the mean age of participants ranged from 27 (Schmahl et al., 2003) to 33 years (Tebartz van Elst et al., 2003). We used standardized diagnoses, established MRI tracing methodologies, examined multiple regions of interest and explored the associations between structural and clinical variables.

4.2. Limitations

4.2.1. Diagnosis

BPD remains a controversial diagnosis in young people. However, BPD criteria can be applied prior to age 18 years (Bernstein et al., 1993), have good concurrent validity (Chanen et al., 2007), show similar stability to adult BPD (Chanen et al., 2004) and are associated with serious morbidity (Bernstein et al., 1993; Chanen et al., 2007).

4.2.2. Design

The cross-sectional design does not allow conclusions to be drawn about structural brain changes over time. Moreover, we studied three regions of interest and cannot comment upon changes in other brain regions. The sample size, although comparable to the larger studies of this kind (Lyoo et al., 1998; Driessen et al., 2000; Irlé et al., 2005), is still small and negative findings might be due to insufficient statistical power.

4.2.3. Treatment and comorbidity

Although BPD participants had minimal prior exposure to treatment, just over half of the sample was 6 to 12 months into a specialized BPD treatment program. Despite this, our analyses comparing groups scanned at baseline to those in treatment failed to show any significant differences in brain morphology. Psychotropic medication use was low but might also have had an impact upon the findings.

The study design reduced the effects of duration of illness factors upon brain morphology. However, ‘comorbidity’ might still have been a potential confounding problem, as mood, anxiety and disruptive behavior disorders, and cannabis dependence were all highly prevalent. Comorbidity is the norm even in early presentations of BPD (Chanen et al., 2007) and excluding such participants would not adequately address this problem, as the sample would become highly atypical. We explored this problem through our analyses comparing groups with and without selected comorbid mental disorders, which did not reveal any significant differences in brain morphology.

4.2.4. Exploratory analyses

The correlations between structural volumes and clinical features should be interpreted with caution because of the exploratory nature of these analyses and because individual SCID-II items are rudimentary measures of specific features of BPD, such as impulsivity or anger. However, the overall pattern of results is consistent. Also, a large number of statistical analyses were used, leading to the possibility of inflated Type I error. Finally, possible mechanisms for the observed relationships between structural volumes and clinical features remain speculative.

4.3. Conclusion

Our findings suggest that the frontal lobe structural changes observed in adults with established BPD are also apparent in teenagers with first-presentation BPD but that amygdala and hippocampal changes are not seen at this stage. This suggests either that the latter might only become apparent as the condition progresses or that those with smaller amygdala and hippocampal volumes are more likely to develop a chronic course. These hypotheses are partially supported by our correlational data. Our findings are consistent with current theories of BPD implicating weakening of prefrontal inhibitory control (Lieb et al., 2004) but not necessarily with the suggestion of *simultaneous* limbic disturbance giving rise to hyper-arousal. While it remains unclear how these structural changes relate to the functioning of the regions studied, these findings highlight the importance of conducting longitudinal studies, commencing at an earlier age, to clarify the timing of the frontal lobe changes and to reconcile differences in medial temporal lobe structures found in adults with BPD.

Acknowledgements

The authors thank the patients and staff of the HYPE Clinic at ORYGEN Youth Health. Thanks are also due to Ms Caroline Weinstein, A/Prof. Warrick Brewer and Ms Deidre Smith for assistance with data collection and to Dr Jem Riffkin for assistance with imaging analysis.

Funding/support: This work was supported in part by grants 98-0198 from the Victorian Health Promotion Foundation, Melbourne, Australia and grant 990748 from the National Health and Medical Research Council (NHMRC), Canberra, Australia. ORYGEN Research Centre is supported by an unrestricted grant from the Colonial Foundation, Melbourne, Australia. Neuroimaging analysis was facilitated by the Melbourne Neuropsychiatry Centre’s Imaging Laboratory, managed by

Ms Bridget Soulsby and supported by Neurosciences Victoria. Dr Stephen Wood is supported by an NHMRC Clinical Career Development Award and a NARSAD Young Investigator Award. Dr Murat Yücel is supported by NHMRC Program Grant 350241.

References

- Achenbach, T.M., 1991. Manual for the Youth Self-report and 1991 Profiles. University of Vermont, Department of Psychiatry, Burlington, VT.
- Achenbach, T.M., 1997. Manual for the Young Adult Self-report and Young Adult Behavior Checklist. University of Vermont, Department of Psychiatry, Burlington, VT.
- Berlin, H.A., Rolls, E.T., Iversen, S.D., 2005. Borderline personality disorder, impulsivity, and the orbitofrontal cortex. *American Journal of Psychiatry* 162, 2360–2373.
- Bernstein, D.P., Cohen, P., Velez, C.N., Schwab-Stone, M., Siever, L.J., Shinsato, L., 1993. Prevalence and stability of the DSM-III-r personality disorders in a community-based survey of adolescents. *American Journal of Psychiatry* 150, 1237–1243.
- Best, M., Williams, J.M., Coccaro, E.F., 2002. Evidence for a dysfunctional prefrontal circuit in patients with an impulsive aggressive disorder. *Proceedings of the National Academy of Sciences of the United States of America* 99, 8448–8453.
- Brambilla, P., Soloff, P.H., Sala, M., Nicoletti, M.A., Keshavan, M.S., Soares, J.C., 2004. Anatomical MRI study of borderline personality disorder patients. *Psychiatry Research. Neuroimaging* 131, 125–133.
- Chanen, A.M., Jackson, H.J., McGorry, P.D., Allott, K.A., Clarkson, V., Yuen, H.P., 2004. Two-year stability of personality disorder in older adolescent outpatients. *Journal of Personality Disorders* 18, 526–541.
- Chanen, A.M., Jovev, M., Jackson, H.J., 2007. Adaptive functioning and psychiatric symptoms in adolescents with borderline personality disorder. *Journal of Clinical Psychiatry* 68, 297–306.
- Convit, A., McHugh, P., Wolf, O.T., de Leon, M.J., Bobinski, M., De Santi, S., Roche, A., Tsui, W., 1999. MRI volume of the amygdala: a reliable method allowing separation from the hippocampal formation. *Psychiatry Research. Neuroimaging* 90, 113–123.
- Cook, M.J., Fish, D.R., Shorvon, S.D., Straughan, K., Stevens, J.M., 1992. Hippocampal volumetric and morphometric studies in frontal and temporal lobe epilepsy. *Brain* 115 (Pt 4), 1001–1015.
- De Bellis, M.D., Hall, J., Boring, A.M., Frustaci, K., Moritz, G., 2001. A pilot longitudinal study of hippocampal volumes in pediatric maltreatment-related posttraumatic stress disorder. *Biological Psychiatry* 50, 305–309.
- De la Fuente, J.M., Goldman, S., Stanus, E., Vizuete, C., Morlan, I., Bobes, J., Mendlewicz, J., 1997. Brain glucose metabolism in borderline personality disorder. *Journal of Psychiatric Research* 31, 531–541.
- Diessen, M., Herrmann, J., Stahl, K., Zwaan, M., Meier, S., Hill, A., Osterheider, M., Petersen, D., 2000. Magnetic resonance imaging volumes of the hippocampus and the amygdala in women with borderline personality disorder and early traumatization. *Archives of General Psychiatry* 57, 1115–1122.
- Eritaia, J., Wood, S.J., Stuart, G.W., Bridle, N., Dudgeon, P., Maruff, P., Velakoulis, D., Pantelis, C., 2000. An optimized method for estimating intracranial volume from magnetic resonance images. *Magnetic Resonance in Medicine* 44, 973–977.
- Eslinger, P.J., Flaherty-Craig, C.V., Benton, A.L., 2004. Developmental outcomes after early prefrontal cortex damage. *Brain and Cognition* 55, 84.
- First, M.B., Gibbon, M., Spitzer, R.L., Williams, J.B.W., 1996. Structured Clinical Interview for DSM-IV Axis I Disorders—Patient Version (SCID-I/P). Biometrics Research Department, New York State Psychiatric Institute, New York, NY.
- First, M.B., Gibbon, M., Spitzer, R.L., Williams, J.B.W., Benjamin, L.S., 1997. User's Guide for the Structured Clinical Interview for DSM-IV Axis II Personality Disorders. American Psychiatric Press, Washington, DC.
- Goyer, P.F., Andreason, P.J., Semple, W.E., Clayton, A.H., King, A.C., Compton-Toth, B.A., Schulz, S.C., Cohen, R.M., 1994. Positron-emission tomography and personality disorders. *Neuropsychopharmacology* 10, 21–28.
- Hazlett, E.A., New, A.S., Newmark, R., Haznedar, M.M., Lo, J.N., Speiser, L.J., Chen, A.D., Mitropoulou, V., Minzenberg, M., Siever, L.J., Buchsbaum, M.S., 2005. Reduced anterior and posterior cingulate gray matter in borderline personality disorder. *Biological Psychiatry* 58, 614–623.
- Irle, E., Lange, C., Sachsse, U., 2005. Reduced size and abnormal asymmetry of parietal cortex in women with borderline personality disorder. *Biological Psychiatry* 57, 173–182.
- Kaufman, J., Birmaher, B., Brent, D., Rao, U., Flynn, C., Moreci, P., Williamson, D., Ryan, N., 1997. Schedule for Affective Disorders and Schizophrenia for School-age Children—Present and Lifetime Version (K-SADS-PL): initial reliability and validity data. *Journal of the American Academy of Child and Adolescent Psychiatry* 36, 980–988.
- Leyton, M., Okazawa, H., Diksic, M., Paris, J., Rosa, P., Mzengeza, S., Young, S.N., Blier, P., Benkelfat, C., 2001. Brain regional α - ^{11}C methyl-L-tryptophan trapping in impulsive subjects with borderline personality disorder. *American Journal of Psychiatry* 158, 775–782.
- Lieb, K., Zanarini, M.C., Schmahl, C., Linehan, M.M., Bohus, M., 2004. Borderline personality disorder. *The Lancet* 364, 453–461.
- Lyoo, I.K., Han, M.H., Cho, D.Y., 1998. A brain MRI study in subjects with borderline personality disorder. *Journal of Affective Disorders* 50, 235–243.
- New, A.S., Hazlett, E.A., Buchsbaum, M.S., Goodman, M., Reynolds, D., Mitropoulou, V., Sprung, L., Shaw Jr, R.B., Koenigsberg, H., Platholi, J., Silverman, J., Siever, L.J., 2002. Blunted prefrontal cortical ^{18}F fluorodeoxyglucose positron emission tomography response to meta-chlorophenylpiperazine in impulsive aggression. *Archives of General Psychiatry* 59, 621–629.
- Pujol, J., Lopez-Sala, A., Deus, J., Cardoner, N., Sebastian-Galles, N., Conesa, G., Capdevila, A., 2002. The lateral asymmetry of the human brain studied by volumetric magnetic resonance imaging. *Neuroimage* 17, 670–679.
- Raine, A., Lencz, T., Bihler, S., LaCasse, L., Colletti, P., 2000. Reduced prefrontal gray matter volume and reduced autonomic activity in antisocial personality disorder. *Archives of General Psychiatry* 57, 119–127.
- Riffkin, J., Yücel, M., Maruff, P., Wood, S.J., Soulsby, B., Olver, J., Kyrios, M., Velakoulis, D., Pantelis, C., 2005. A manual and automated MRI study of anterior cingulate and orbito-frontal cortices, and caudate nucleus in obsessive-compulsive disorder: comparison with healthy controls and patients with schizophrenia. *Psychiatry Research. Neuroimaging* 138, 99–113.
- Robb, R.A., 2001. The biomedical imaging resource at Mayo Clinic. *IEEE Transactions on Medical Imaging* 20, 854–867.

- Rosso, I.M., Cintron, C.M., Steingard, R.J., Renshaw, P.F., Young, A.D., Yurgelun-Todd, D.A., 2005. Amygdala and hippocampus volumes in pediatric major depression. *Biological Psychiatry* 57, 21–26.
- Rusch, N., van Elst, L.T., Ludaescher, P., Wilke, M., Huppertz, H.J., Thiel, T., Schmahl, C., Bohus, M., Lieb, K., Hesslinger, B., Hennig, J., Ebert, D., 2003. A voxel-based morphometric MRI study in female patients with borderline personality disorder. *Neuroimage* 20, 385–392.
- Schmahl, C.G., Bremner, J.D., 2006. Neuroimaging in borderline personality disorder. *Journal of Psychiatric Research* 40, 419–427.
- Schmahl, C.G., Vermetten, E., Elzinga, B.M., Bremner, J.D., 2003. Magnetic resonance imaging of hippocampal and amygdala volume in women with childhood abuse and borderline personality disorder. *Psychiatry Research: Neuroimaging* 122, 193–198.
- Schmahl, C.G., Vermetten, E., Elzinga, B.M., Bremner, J.D., 2004. A positron emission tomography study of memories of childhood abuse in borderline personality disorder. *Biological Psychiatry* 55, 759–765.
- Schulz, S.C., Koller, M.M., Kishore, P.R., Hamer, R.M., Gehl, J.J., Friedel, R.O., 1983. Ventricular enlargement in teenage patients with schizophrenia spectrum disorder. *American Journal of Psychiatry* 140, 1592–1595.
- Siever, L.J., Torgersen, S., Gunderson, J.G., Livesley, W., Kendler, K.S., 2002. The borderline diagnosis III: identifying endophenotypes for genetic studies. *Biological Psychiatry* 51, 964–968.
- Smith, S.M., 2002. Fast robust automated brain extraction. *Human Brain Mapping* 17, 143–155.
- Soloff, P.H., Meltzer, C.C., Greer, P.J., Constantine, D., Kelly, T.M., 2000. A fenfluramine-activated FDG-PET study of borderline personality disorder. *Biological Psychiatry* 47, 540–547.
- Soloff, P.H., Meltzer, C.C., Becker, C., Greer, P.J., Kelly, T.M., Constantine, D., 2003. Impulsivity and prefrontal hypometabolism in borderline personality disorder. *Psychiatry Research: Neuroimaging* 123, 153–163.
- Tebartz van Elst, L., Hesslinger, B., Thiel, T., Geiger, E., Haegele, K., Lemieux, L., Lieb, K., Bohus, M., Hennig, J., Ebert, D., 2003. Frontolimbic brain abnormalities in patients with borderline personality disorder — a volumetric magnetic resonance imaging study. *Biological Psychiatry* 54, 163–171.
- Velakoulis, D., Wood, S.J., Wong, M.T., McGorry, P.D., Yung, A., Phillips, L., Smith, D., Brewer, W., Proffitt, T., Desmond, P., Pantelis, C., 2006. Hippocampal and amygdala volumes according to psychosis stage and diagnosis: a magnetic resonance imaging study of chronic schizophrenia, first-episode psychosis, and ultra-high-risk individuals. *Archives of General Psychiatry* 63, 139–149.
- Zetzsche, T., Frodl, T., Preuss, U.W., Schmitt, G., Seifert, D., Leinsinger, G., Born, C., Reiser, M., Moller, H.J., Meisenzahl, E.M., 2006. Amygdala volume and depressive symptoms in patients with borderline personality disorder. *Biological Psychiatry* 60, 302–310.
- Zhang, Y., Brady, M., Smith, S., 2001. Segmentation of brain MR images through a hidden Markov random field model and the expectation–maximization algorithm. *IEEE Transactions on Medical Imaging* 20, 45–57.